



Int J Trichology. 2015 Apr-Jun; 7(2): 87–89.

PMCID: PMC4502486

doi: [10.4103/0974-7753.160125](https://doi.org/10.4103/0974-7753.160125)

Lichen Planopilaris with Autoimmune Thyroiditis

[Ujjawal Khurana](#), [Kaushik Majumdar](#), [Dinesh Asati](#),¹ [Deepti Joshi](#), [Garima Goel](#), and [Neelkamal Kapoor](#)

Department of Pathology and Laboratory Medicine, All India Institute of Medical Sciences, Saket Nagar, Bhopal, Madhya Pradesh, India

¹Department of Dermatology, All India Institute of Medical Sciences, Saket Nagar, Bhopal, Madhya Pradesh, India

Address for correspondence: Dr. Kaushik Majumdar, Department of Pathology and Laboratory Medicine, All India Institute of Medical Sciences, Saket Nagar, Bhopal, Madhya Pradesh, India. E-mail: drkaushik.m@gmail.com

Copyright : © International Journal of Trichology

This is an open-access article distributed under the terms of the Creative Commons Attribution-Noncommercial-Share Alike 3.0 Unported, which permits unrestricted use, distribution, and reproduction in any medium, provided the original work is properly cited.

Sir,

Lichen planopilaris (LPP) is an immune-mediated scarring alopecia, histologically characterized by perifollicular lymphocytic infiltrate and progressive fibrosis, leading to the destruction of the pilosebaceous units. Autoimmune thyroid disorders are usually associated with nonscarring alopecia, like diffuse alopecia or alopecia areata (AA).^[1,2,3,4,5] We discuss a rare co-existence of Hashimoto's thyroiditis (HT) with scarring alopecia due to LPP, thereby highlighting the importance of evaluating thyroid profile in patients with LPP.

A 35-year-old female presented with swelling anterior neck, painful deglutition, and cold intolerance for 4 years. Thyroid function tests revealed a hypothyroid profile, after which she was put on thyroid hormone replacement. High-resolution sonography showed diffusely enlarged right lobe of the thyroid gland (5.5 cm × 4.0 cm) with heterogeneous echotexture and multiple tiny hypoechoic nodules. Fine-needle aspiration (FNA) smears from the right lobe revealed clusters of follicular epithelial cells with abundant lymphocytic and plasma cell infiltration. Follicular destruction, Hürthle cell change, epithelioid histiocytes, and multinucleate giant cells were also seen, consistent with HT [\[Figure 1\]](#). Serum antimicrosomal antibody titer was high (203 IU/ml; normal < 34 IU/ml). Complete hemogram, blood sugar, lipid profile, and serum anti-nuclear antibody were within normal limits.

The patient also complained of itching and irritation in the scalp, with the loss of hair and scaling since 1.5 years. The dermatological evaluation revealed an irregular 6 cm × 4 cm scarring alopecia on the right temporoparietal region [\[Figure 2a\]](#) and an oblong 5 cm × 2 cm similar area on the left temporal region. Follicular plugs, focal violaceous brown discoloration and residual tufts of hair were seen. Incision biopsy from the scalp lesion showed atrophied epidermis, follicular plugging, wedge-shaped hypergranulosis, elongated rete ridges, and basal vacuolar degeneration. The dermis showed a marked loss of pilosebaceous units with perifollicular fibrosis, resulting in dense fibrous tracts. Pigment incontinence, sparse perifollicular, and perivascular lymphocytic infiltrate were also seen [\[Figure 2b\]](#). The histopathological features were consistent with LPP. The patient was put on oral and topical corticosteroids along with thyroid hormone supplement; follow-up visits showed gradual symptomatic improvement.

Lichen planopilaris usually occurs in the middle-aged, with females being affected more than males.^[6] In due course, it may progress to marked fibrosis, morphologically resembling Pseudopelade of Brocq. Both lichen planus (LP) and LPP are often associated with other immunological conditions such as thymoma,

myasthenia gravis, dermatitis herpetiformis, vitiligo, hepatitis, Crohn's disease, and ulcerative colitis.[2]

Alopecia in thyroid disorders is usually noncicatricial, such as diffuse alopecia, AA or androgenetic alopecia. [3,4,5,7] Association of alopecia and thyroid dysfunction has been found in conditions such as chronic urticaria, vitiligo, acanthosis nigricans, psoriasis, and seborrheic dermatitis.[4,5] Thyroid abnormalities in these situations include thyroiditis, cysts, nodules, and rarely papillary thyroid carcinoma.[7] Autoimmune diseases associated with HT include type I diabetes mellitus, systemic lupus erythematosus, and celiac disease.[8]

The association of scarring alopecia due to LPP with thyroid disorders has been rarely described.[1,2] A retrospective case-control study showing an association of LPP and thyroid diseases involving 166 cases has mentioned 10 cases of HT.[1] However, the study could have been more elaborative if it had provided some histological illustrations and mentioned the number of cases in which scalp biopsy, thyroid aspiration cytology, ultrasonography, thyroid function tests, and serum antimicrosomal antibody were available. In our recently established center, six other patients diagnosed with LPP during a span of one year did not show clinical or biochemical evidence of thyroid dysfunction.

Two recently published studies show an association of another lichenoid lesion, oral LP with thyroid disorders, including HT.[9,10] A predisposing role of HT may be suggested in the context that circulating antithyroid antibodies may trigger an autoimmune response in the mucosa and skin, leading to the development of lichenoid lesions.[10]

Treatment strategies for LPP are challenging; immunosuppressive and anti-inflammatory agents are mainly targeted toward symptomatic relief, control of inflammation, and arrest of hair loss. Damage is permanent in areas of follicular destruction, and hair regrowth is usually not possible.[6]

To conclude, although non-scarring alopecia like AA is known to be associated with thyroid disorders, co-occurrence of scarring alopecia due to LPP and autoimmune thyroid disorders has been seldom described. We herein like to add to the current literature a rare case with thyroid enlargement, which revealed HT on FNA and serum assays, with associated progressive scarring alopecia due to LPP. This association highlights the importance of evaluating the thyroid profile in patients with cicatricial alopecia due to LPP.

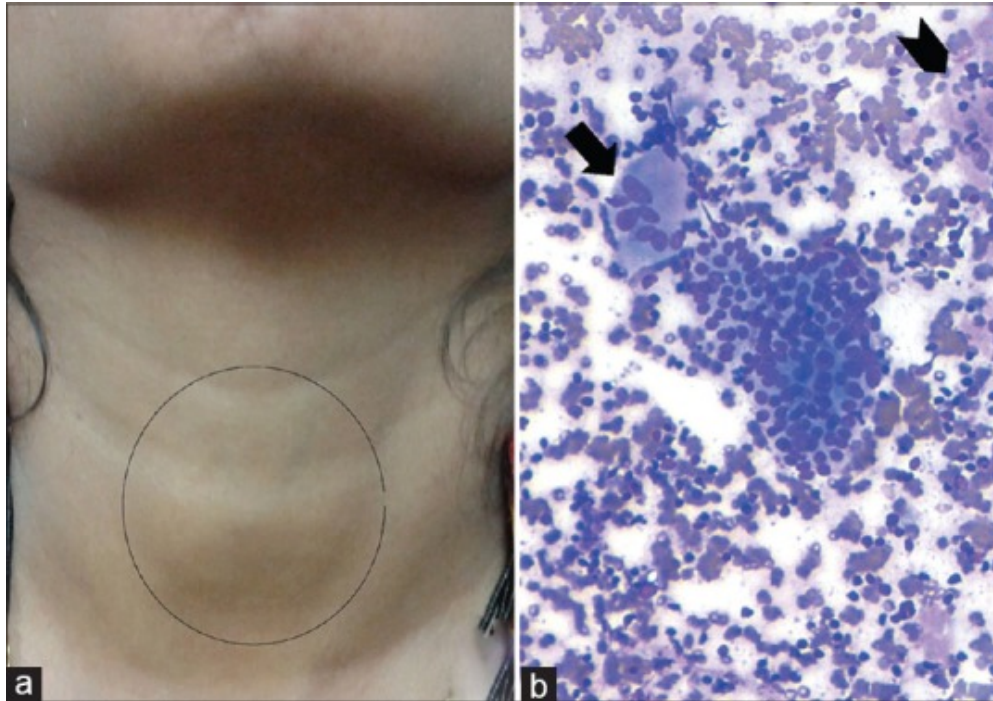
REFERENCES

1. Atanaskova Mesinkovska N, Brankov N, Piliang M, Kyei A, Bergfeld WF. Association of lichen planopilaris with thyroid disease: A retrospective case-control study. *J Am Acad Dermatol*. 2014;70:889–92. [PubMed: 24569115]
2. Rosina P, Chierigato C, Magnanini M, Barba A. Lichen planopilaris and autoimmune thyroiditis. *J Eur Acad Dermatol Venereol*. 2002;16:648–9. [PubMed: 12482063]
3. Lyakhovitsky A, Shemer A, Amichai B. Increased prevalence of thyroid disorders in patients with new onset alopecia areata. *Australas J Dermatol*. 2015;56:103–6. [PubMed: 25303421]
4. Vincent M, Yogiraj K. A descriptive study of alopecia patterns and their relation to thyroid dysfunction. *Int J Trichology*. 2013;5:57–60. [PMCID: PMC3746235] [PubMed: 23960405]
5. Ishak RS, Piliang MP. Association between alopecia areata, psoriasis vulgaris, thyroid disease, and metabolic syndrome. *J Investig Dermatol Symp Proc*. 2013;16:S56–7.
6. Assouly P, Reygagne P. Lichen planopilaris: Update on diagnosis and treatment. *Semin Cutan Med Surg*. 2009;28:3–10. [PubMed: 19341936]
7. Lo Sicco K, McGuire S, English JC., 3rd A retrospective study of thyroid structural abnormalities in alopecia patients. *Dermatoendocrinol*. 2011;3:251–4. [PMCID: PMC3256342] [PubMed: 22259653]

8. Radetti G. Clinical aspects of Hashimoto's thyroiditis. *Endocr Dev.* 2014;26:158–70. [PubMed: 25231451]
9. Siponen M, Huuskonen L, Läärä E, Salo T. Association of oral lichen planus with thyroid disease in a Finnish population: A retrospective case-control study. *Oral Surg Oral Med Oral Pathol Oral Radiol Endod.* 2010;110:319–24. [PubMed: 20656530]
10. Lo Muzio L, Santarelli A, Campisi G, Lacaita M, Favia G. Possible link between Hashimoto's thyroiditis and oral lichen planus: A novel association found. *Clin Oral Investig.* 2013;17:333–6.

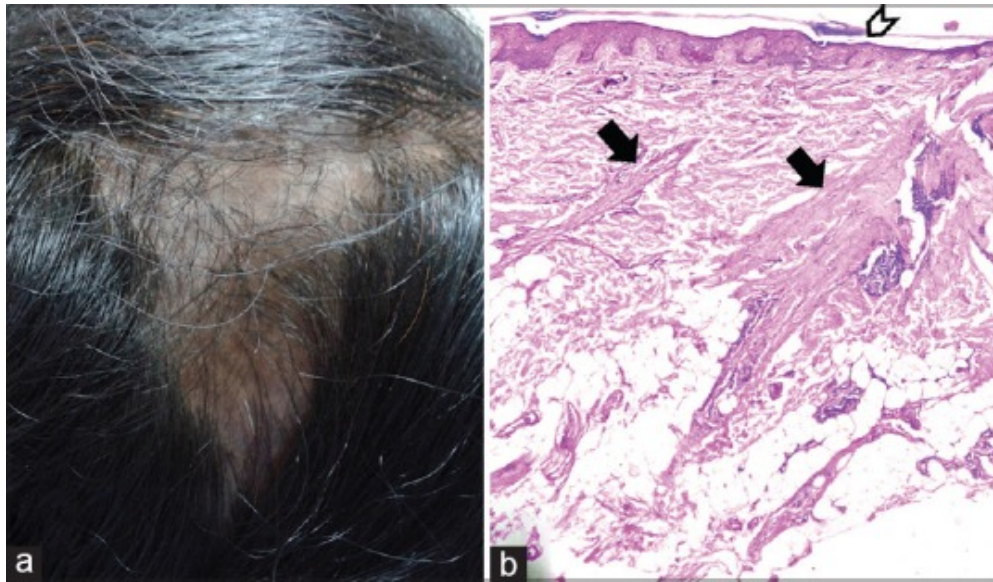
Figures and Tables

Figure 1



(a) Hashimoto's thyroiditis. Mild diffuse enlargement of the thyroid gland (encircled), right lobe more than left; (b) fine-needle aspiration smears showing cluster of follicular epithelial cells with abundant infiltrating lymphocytes, along with a multinucleate giant cell (arrow); background showing colloid (arrow head) and excess of lymphocytes (Giemsa, $\times 200$)

Figure 2



(a) Lichen planopilaris (LPP). An irregular scarred area on the right temporoparietal region, with some remaining tufts of hair; (b) photomicrograph showing advanced LPP with atrophied epidermis, follicular plugging (arrow head), and marked perifollicular fibrosis resulting in dense fibrous tracts (arrow); pigment incontinence and patchy perifollicular lymphocytic infiltrate are noted (H and E, $\times 200$)

Articles from International Journal of Trichology are provided here courtesy of **Medknow Publications**